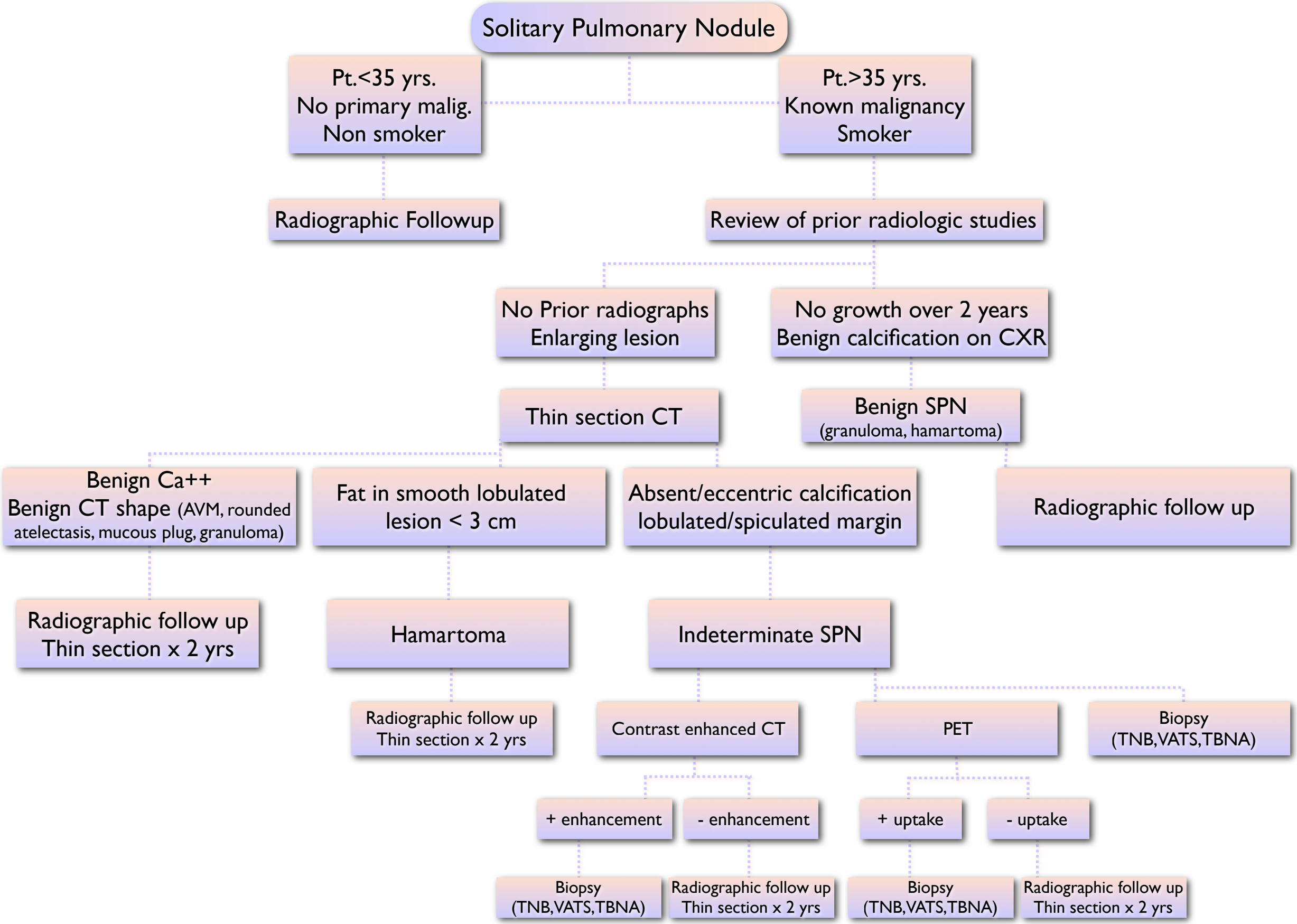
Solitary Pulmonary Nodule
Pt.<35 yrs.
No primary malig.
Non smoker
Pt.>35 yrs.
Known malignancy
Smoker
Radiographic Followup
Review of prior radiologic studies
No Prior radiographs
Enlarging lesion
No growth over 2 years
Benign calcification on CXR
Thin section CT
Benign SPN
(granuloma, hamartoma)
Benign Ca++
Benign CT shape (AVM, rounded atelectasis, mucous plug, granuloma)
Fat in smooth lobulated lesion < 3 cm
Absent/eccentric calcification lobulated/spiculated margin
Radiographic follow up
Radiographic follow up
Thin section x 2 yrs
Hamartoma
Indeterminate SPN
Radiographic follow up
Thin section x 2 yrs
Contrast enhanced CT
PET
Biopsy
(TNB,VATS,TBNA)
+ enhancement
- enhancement
+ uptake
- uptake
Biopsy
(TNB,VATS,TBNA)
Radiographic follow up
Thin section x 2 yrs
Biopsy
(TNB,VATS,TBNA)
Radiographic follow up
Thin section x 2 yrs